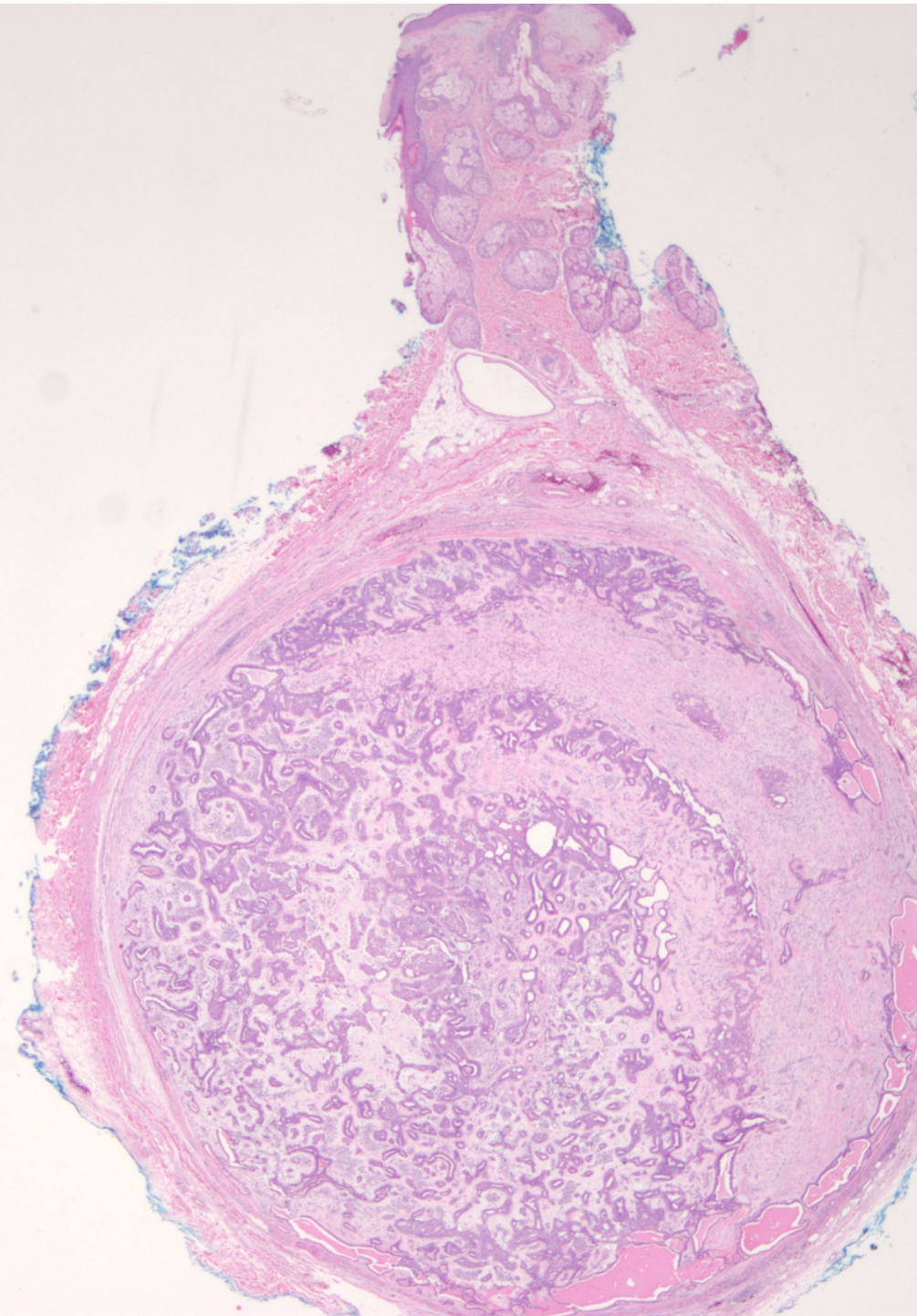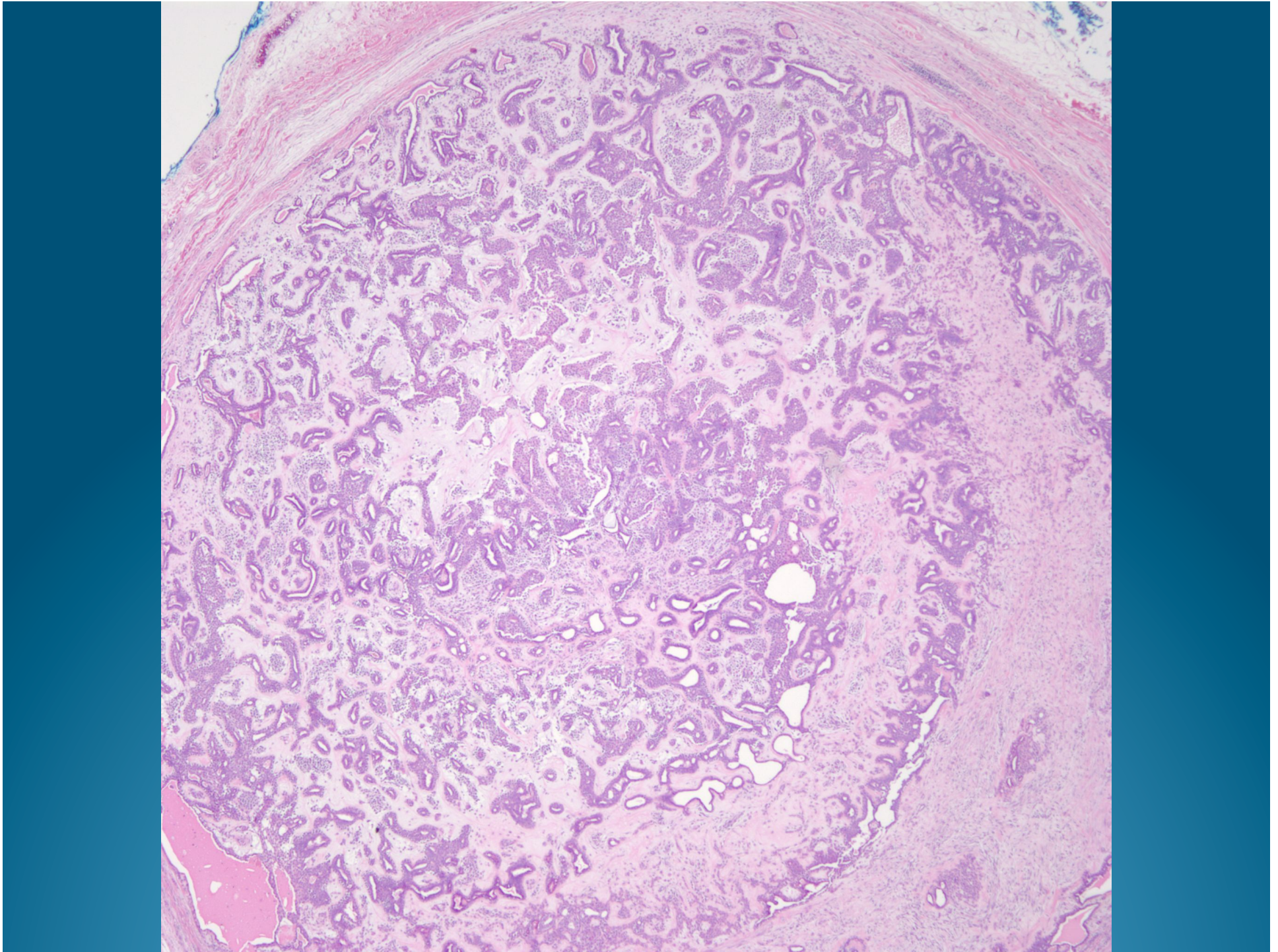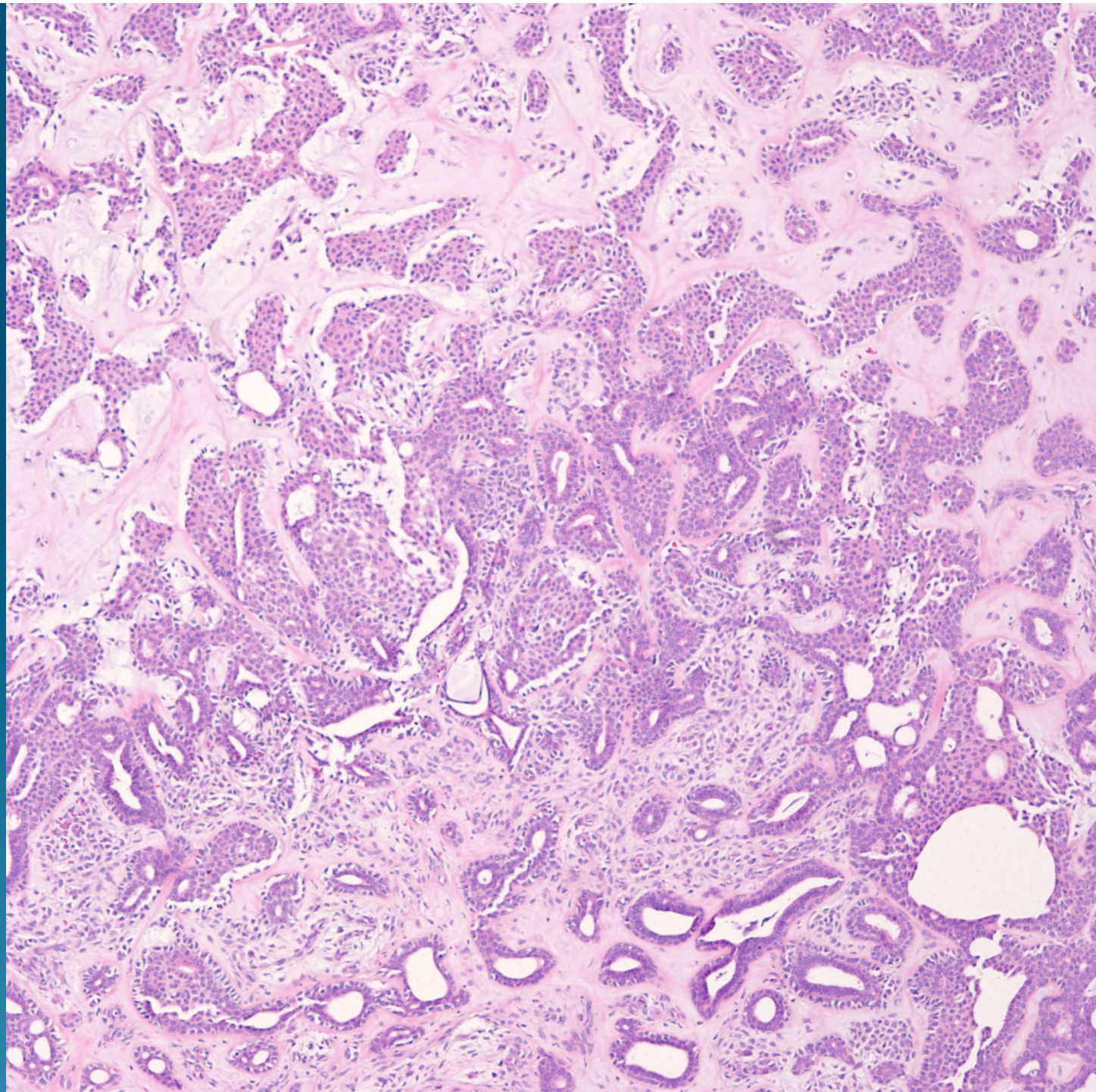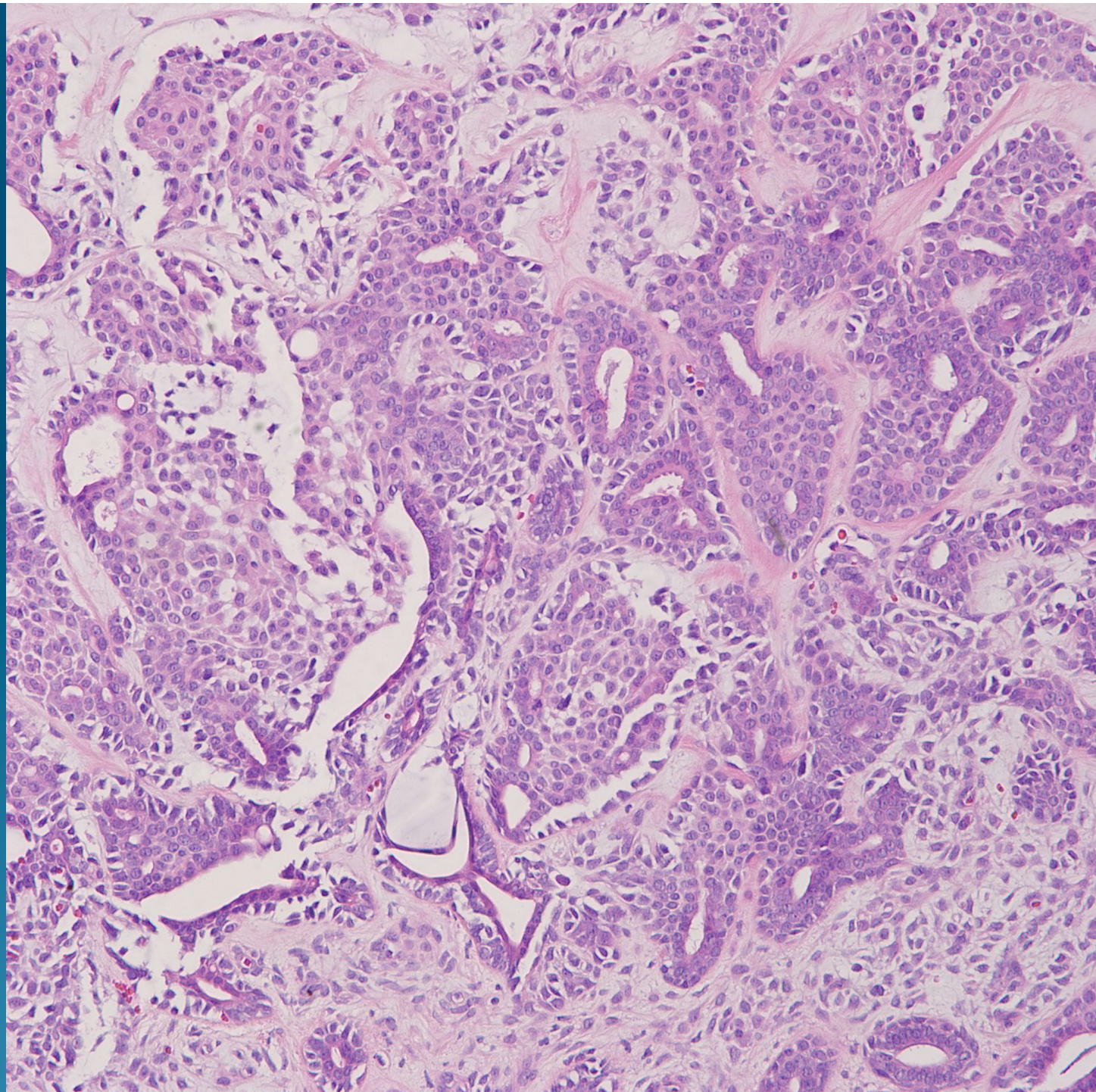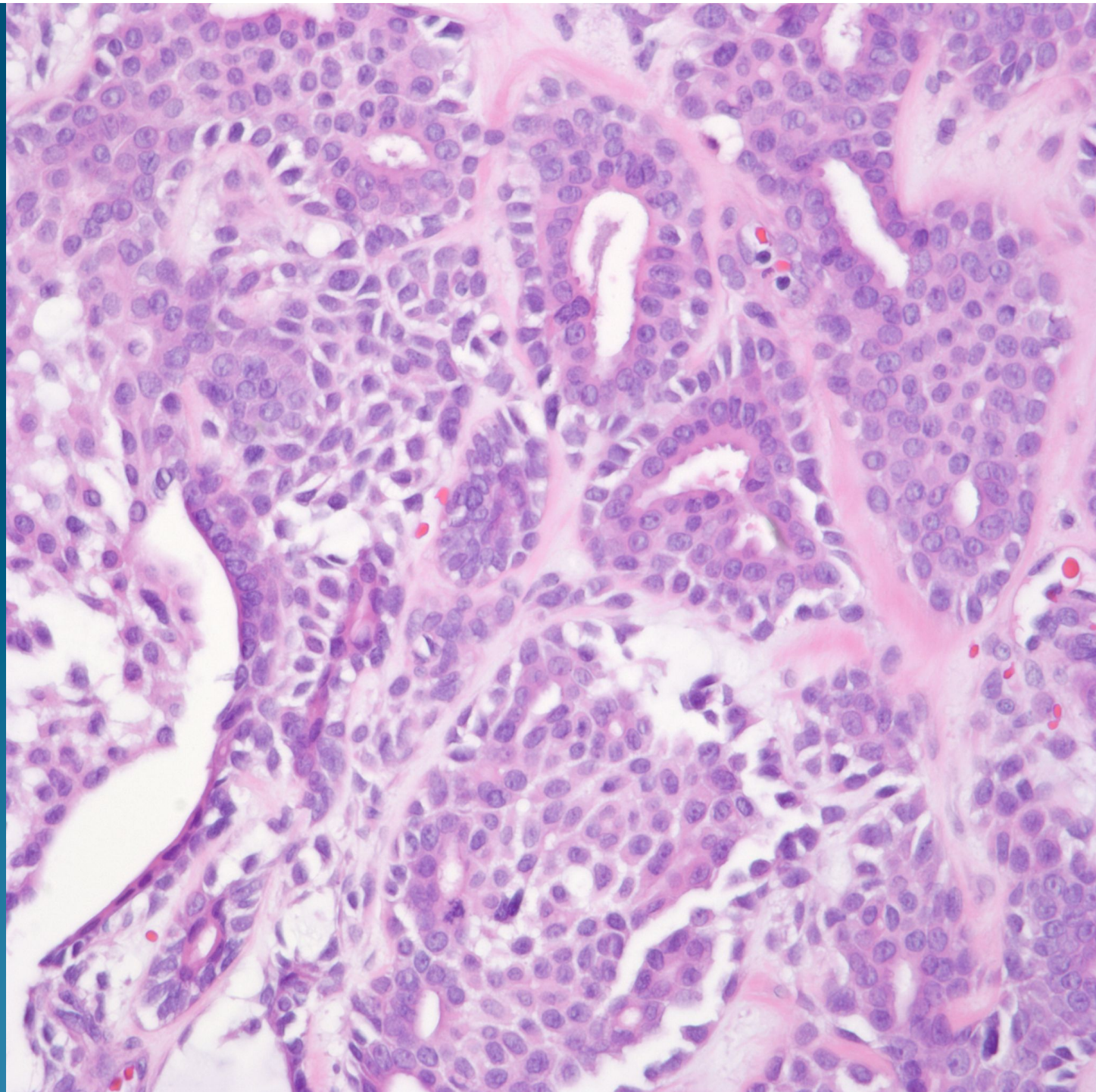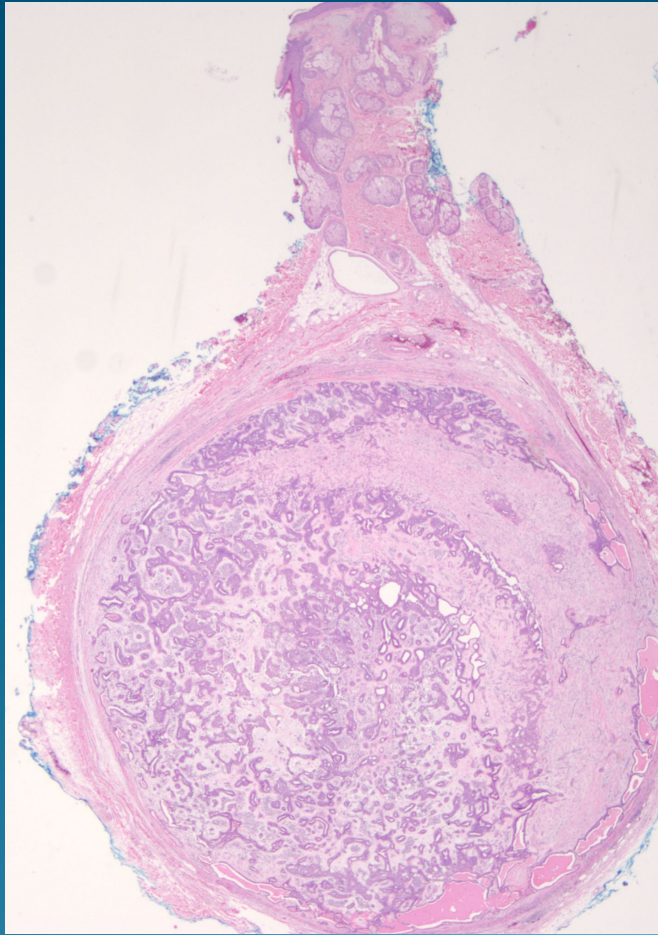


What is the best diagnosis?

- A. Metastatic Adenocarcinoma from the Breast
- B. Metastatic Renal Cell Carcinoma
- C. Chondroid Syrginoma
- D. Nodular and Cystic Hidradenoma
- E. Glomus Tumor

Chondroid Syringoma (Benign Mixed Tumor of the Skin)

Pearls



- Circumscribed dermal tumor with no epidermal attachment
- Variable mix of epithelial and stroma components
- Epithelium in tubules and cords and may show squamous and apocrine/eccrine differentiation
- Stroma is chondroid and myxoid